

Dr. Neal Alpiner: MD
William Beaumont Hospital
White paper and results to be presented at national PM&R conference 2004

Results Summary

The Role of Functional MRI in Defining Auditory-Motor Processing Networks

OBJECTIVE: To determine if existing auditory-motor processing networks can be augmented through specific auditory-motor sequencing tasks, effectively training the brain through synaptic modulation.

METHODS: Seven normal adults (age 26-64; 4M, 3F) were selected because of their extensive training in Interactive Metronome* (brain-based computer driven auditory-motor sequencing program). One subject without IM training was used for control. fMRI was selected because of its ability to correlate cerebral blood flow with neuronal activity via changes in deoxyhemoglobin. The subjects were placed in the scanner, instructed to use the scanner's internal cycling noise ("chirping") to simulate IM auditory cues. These guide sound cues allowed for the subject to recreate learned auditory-motor behaviors. All subjects used right hand-leg neuropatterns. 512 images were acquired during the subject's 30 second on/off performance. Images were acquired using T1 weighted echo, TE 60 ms, TR 3 sec, flip angle 90 degrees, 1.5 MRI system.

RESULTS: 5/7 subjects revealed increased activity at right Calcrine Sulcus, 3/7 showed bilateral increased activity at Cingulate Gyrus. 5/7 subjects showed increased activity at left posterior Temporal Gyrus, 2 patients show bilateral increased temporal activity. 3/7 patients show increased activation at right superior Frontal Gyrus, 4/7 patients showed increase at left Superior Frontal Gyrus with 1 patient revealing bilateral activation. 3/7 patients showed activation at left Posterior Central Gyrus. The 1 patient without IM training had absent activity.

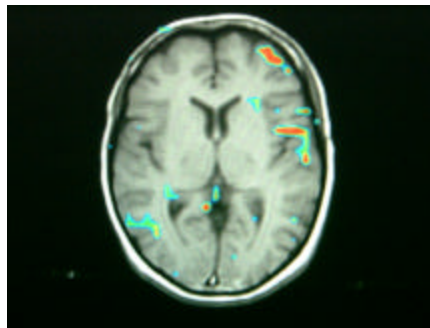
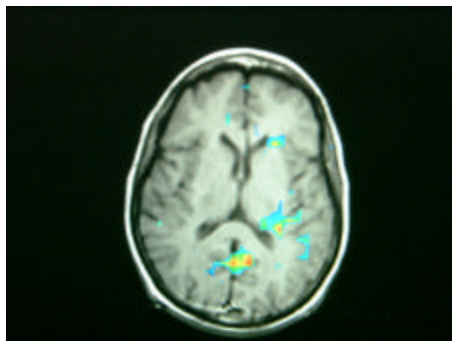
CONCLUSION: Auditory-motor processing is complex, working through multipal neuronetworks. This present study provides a preliminary analysis of possible structures involved, specifically: Cingulate Gyrus, Temporal Gyrus, Superior Frontal Gyrus. Of note is the significance of bilateral activation for these tasks. Repetitive auditory-motor training, specifically IM holds promise for neuroplasticity of higher and lower brain centers.

fMRI Study Summary

"We know there are certain key regions of the brain acting simultaneously to control multi-system neural networks- cognition, emotional, sensory and motor function - much like Grand Central Station controlling subway traffic. This initial study allows us to correlate theory with reality; proposed mechanism of action with actual mechanism of action. That is what makes this work exciting,"

Neil Alpin, MD.

Results from Early Clinical Trials



Results from a Pilot fMRI (Brain Scan) study show IM Directly Activates Multiple Parts of the "Neuronetwork"

Cingulate Gyrus

- Allows Shifting of Attention & Focus
- Cognitive Flexibility

Basal Ganglia

- Integrates Thought and Movement

Medial Brainstem

- Neuro-Motor Pipeline

Key Findings

- These parts of the brain (Cingulate Gyrus, Basal Ganglia, & Medial Brainstem) provide input/output connections to frontal lobes, where cognitive and motor processing occurs.
- IM exercises strengthen the "neuronetworks" to make the transmission of information between areas faster and with greater accuracy.

IM Training is Based on Several Medical Theories:

- Motor planning processes of organizing and sequencing are based on an internal sense of rhythm.
- Prefrontal and striatal regions of the brain are responsible for high-order motor control.
- Timing training can improve neuromuscular connections.